

Updated Overview on Pathogenesis and Treatment Approaches of Focal Segmental Glomerulosclerosis

¹Raad Yousef Abdulaziz Altalhi, ²Mohammed Hassan Saeed Baali,
³Abdullah Ahmed Hassan Almalki, ⁴Abdulrahman Helal Safer Alzaidi,
⁵Saif Khalid D Altalhi

Abstract: The occurrence of focal segmental glomerulosclerosis (FSGS) has actually increased over the previous years and it is presumed to be among the leading reasons for idiopathic nephrotic syndrome in adult patients. The aim of this systematic review was to summarize the progress related to treatment techniques in adult FSGS over the past twenty years and evaluate the updated treatments strategies which are offered, as well as to discuss the updates on pathogenesis of FSGS. We performed a systematic review of English-language short articles through MEDLINE and PreMedline, and to evaluate literature-based publications over the last two decades, the MEDLINE database search was limited to a period ranging from January 1980 to November 2016. The search was conducted utilizing the keywords "focal segmental glomerulosclerosis" AND "treatment", Pathogenesis. Restricting the time frame to the last 20 years would enable access to a majority of recognized manuscripts. Recent studies recommend that primary FSGS might be brought on by plasma-borne aspects that increase glomerular permeability to albumin. Treatment with plasma exchange ended up being a rational action when a number of subtypes of FSGS were discovered to repeat in allograft-transplanted kidneys, and with the discovery of prospective pathological distributing aspects. Plasma exchange changes the patient's blood plasma with a donor plasma item, eliminating prospective pathological aspects from the patient's blood circulation, and has actually shown reliable for dealing with intense autoimmune conditions such as Guillain-Barre syndrome and persistent conditions such as myasthenia gravis.

Keywords: MEDLINE and PreMedline, "focal segmental glomerulosclerosis" AND "treatment", Pathogenesis.

1. INTRODUCTION

FSGS is a pathological syndrome identified by scarred glomeruli, extreme protein excretion, and hurt epithelial podocytes. The primary cause is unidentified in roughly 80 % of cases ⁽¹⁾ and offered treatments have actually restricted efficiency. Even with treatment, 30-- 60 % of patients development to kidney failure within 5-10 years and amongst those who get a kidney transplant, serious proteinuria repeats in 30-55 % of patients, typically within hours or days of grafting ^(2,3,4,5,6). The occurrence of focal segmental glomerulosclerosis (FSGS) has actually increased over the previous years and it is presumed to be among the leading reasons for idiopathic nephrotic syndrome in adult patients. Racial variations have actually been reported with African American being 2 to 3 times more frequently impacted than Caucasian ⁽⁷⁾. Focal segmental glomerulosclerosis provides as a histological pattern of kidney damage with various, multifactorial, and often undefined pathogenesis. FSGS represents among the most severe glomerular illness, with regular development to end-stage kidney disease and a high rate of reoccurrence in kidney allografts. Medical category consists of the following 5 types ^(1,2): Idiopathic or primary FSGS, the etiology which is mainly unidentified; secondary or adaptive FSGS, which typically describes an adaptive action to glomerular hypertrophy/hyperfiltration and which provides a nonspecific pattern of scarring due to a previous injury; hereditary FSGS; drug-induced FSGS; virus-associated FSGS ^(1,2). Medical category of FSGS is based upon assumed etiology, nevertheless in more than 80% of cases the etiology is unidentified and this group is for that reason categorized as having idiopathic or primary disease. FSGS might be secondary to other disease

procedures such as sickle cell disease, weight problems, heroin usage, HIV nephropathy and other glomerulonephritides that are related to nephron loss. Familial cases of FSGS, both non-syndromic and syndromic have actually been reported. This group is most likely accountable for less than 1% of all cases, in-depth molecular research study of genetic kinds has actually assisted advance understanding of the pathogenesis of FSGS ⁽⁸⁾.

The aim of this systematic review was to summarize the progress related to treatment strategies in adult FSGS over the past two decades and evaluate the updated treatments strategies which are available. and also to discuss the updates on pathogenesis of FSGS.

2. METHODOLOGY

We performed a systematic review of English-language short articles through MEDLINE and PreMedline, and to evaluate literature-based publications over the last two decades, the MEDLINE database search was limited to a period ranging from January 1980 to November 2016. The search was conducted utilizing the keywords "focal segmental glomerulosclerosis" AND "treatment", Pathogenesis. Restricting the time frame to the last 20 years would enable access to a majority of recognized manuscripts.

Evaluation authors independently analyzed the titles and abstracts of the determined citations to assess eligibility and disagreement was solved by conversation. Full-texts of potentially qualified studies were then recovered for more assessment and factors for exemption were recorded. Information was drawn out on study and patient characteristics, and on treatment information and outcomes. Research study attributes consisted of year of publication, nation, research study design, number of participants, and median follow-up time. Patient characteristics consisted of age, sex, kind of kidney transplant (living or deceased), level of proteinuria at time of FSGS reoccurrence, biopsy testing, time to recurrence.

3. RESULTS AND DISCUSSION

PATHOGENESIS:

The kidney is responsible for filtering of around 180 liters daily of plasma consisting of over 7,200 g grams of albumin; over 99.9% of albumin is kept by combined actions of selective purification and tubular reuptake ⁽⁹⁾. This policy of filtering of macromolecules is enabled by the glomerular filtering barrier, which is consisted of specialized fenestrated endothelial cells, the glomerular basement membrane (GBM), and glomerular epithelial cells (podocytes) whose distal foot processes are connected to the GBM (**Figure.1**) ⁽¹⁰⁾. Surrounding podocyte foot processes are linked to each other by networks of specialized cell-cell junctions referred to as slit diaphragms. In addition, the GBM has a plentiful supply of negatively-charged heparan sulfate proteoglycans, leading to negatively-charged particles being fairly more limited from passage than positively-charged particles of the exact same size ⁽¹¹⁾. In health, purification of macromolecules reduces with increasing molecular size specifically with particles higher than 42 Å in size or more than 200 kDa ⁽¹²⁾. The upkeep of the GFB depends upon practical and structural interaction in between the 3 parts ^(13,14,15,16,17).

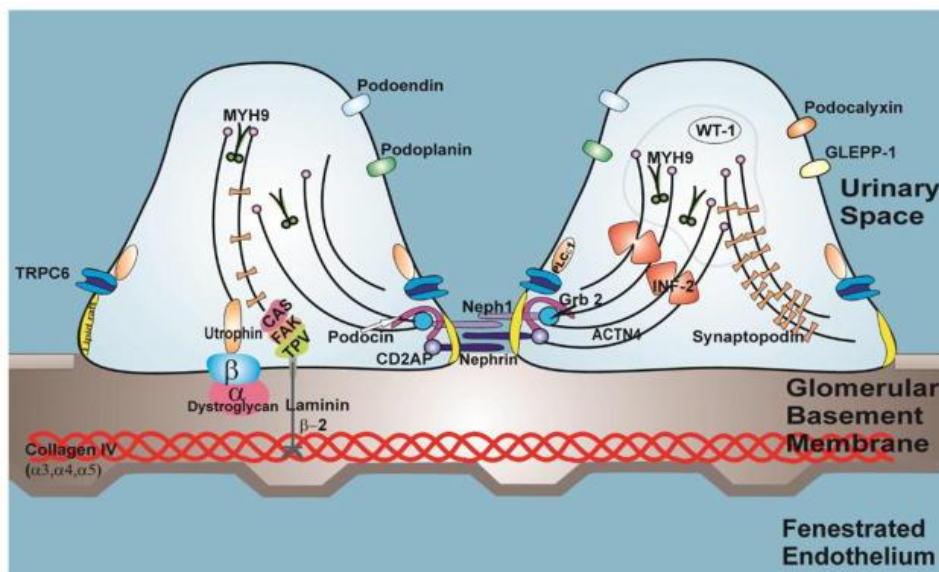


Figure.1: The podocyte and the other components of the glomerular filtration barrier

Several lines of evidence have actually recommended that proteinuria and glomerular histologic changes can be moderated by the direct activity of a flowing aspect. These information were gotten from ex vivo analysis of glomerular modifications after incubation with serum from patients with FSGS, as to start with explained by Sharma et al⁽¹⁸⁾ in 1999, along with from analysis of animal designs where kidneys from a particular line of afflicted mice revealed healing from FSGS after transplant into regular mice⁽¹⁹⁾. The most striking information, nevertheless, was gotten from a research study of a kidney with FSGS reoccurrence that had actually been re-grafted from a patient to another and caused overall regression of the disease⁽²⁰⁾.

In the last few years research study interest has actually concentrated on the soluble type of the urokinase type plasminogen activator receptor (suPAR). suPAR seems able to trigger podocyte foot effacement in mice⁽²¹⁾, and suPAR levels observed in patients with FSGS are greater than those in patients with other glomerulopathies⁽²²⁾. The particular participation of suPAR in glomerulonephritis has actually not been verified by other research studies, which revealed increased (plasma) suPAR levels in other pathological scenarios (i.e., viral and bacterial infections, sepsis, and cancer)⁽²³⁾. Rather, increased suPAR levels were observed mainly in patients with decreased glomerular purification rate (GFR), recommending that an elevation of suPAR levels might simply be an indication of minimized GFR⁽²⁴⁾. The effectiveness of suPAR to identify in between FSGS and non-FSGS glomerulonephritis has actually been questioned by Bock et al⁽²⁵⁾, who revealed comparable (plasma) suPAR levels amongst FSGS patients, non-FSGS controls, and healthy volunteers.

Other distributing aspects, such as cardiothropin-like cytokine 1 (CLC-1), vasodilator-stimulated phosphoprotein and apolipoprotein A-I, have actually likewise been proposed as effectors in the glomerular permeability procedure, however their pathological and scientific functions stay unidentified⁽²⁶⁾. Just recently, detection of a panel of serum antibodies directed to podocyte antigens was discovered to be related to a high portion of regressions in FSGS (predictive reoccurrence value of 92%)⁽²⁷⁾.

4. OVERVIEW OF CURRENT FSGS TREATMENTS

Recent studies recommend that primary FSGS might be brought on by plasma-borne aspects that increase glomerular permeability to albumin⁽³⁾. Treatment with plasma exchange ended up being a rational action when a number of subtypes of FSGS were discovered to repeat in allograft-transplanted kidneys, and with the discovery of prospective pathological distributing aspects^(6,18,28,29). Plasma exchange changes the patient's blood plasma with a donor plasma item, eliminating prospective pathological aspects from the patient's blood circulation, and has actually shown reliable for dealing with intense autoimmune conditions such as Guillain-Barre syndrome and persistent conditions such as myasthenia gravis^(30,31). While present standards support making use of plasma exchange for frequent post-transplant FSGS, proof on treatment effectiveness comes mainly from case reports and unchecked case series⁽³⁾.

First-Line Treatment Options in Focal Segmental Glomerulosclerosis:

Most studies reported on first-line treatment including everyday oral prednisolone and sometimes in mix with other immunosuppressive steps. The overall variety of patients treated with prednisolone varied from 8 to 79 patients in the particular research studies. The general action rate reported in these research studies varied from 50%⁽³²⁾ approximately 68.8% in a potential research study performed in India⁽³³⁾. Follow-up of patients was extremely varied, varying from 16.2 to 62 months. As anticipated, in the research study with the quickest follow-up the regression rate was the most affordable (27.3%)⁽³³⁾, while Rydel and coworkers reported a regression rate of 67%⁽³²⁾. In the research study reporting a single center experience, a bulk got high dosage prednisone for a minimum of one month (87% \geq 60 mg/d) and those staying on high dosage prednisolone treatment revealed a substantial pattern to much better reaction. A multicenter retrospective analysis from Italy exposed remission of 31 from 52 patients treated with steroids (either 1 mg/kg body weight for 8 weeks with subsequent tapering or 3 intravenous pulses of 1 g each followed by 0.5 mg/kg body weight oral prednisolone with subsequent tapering). All consisted of patients had nephrotic variety proteinuria determined a minimum of two times ahead of treatment initiation. Of the 38 patients who did not accomplish either partial or total remission, 26 were pulled away with either extended corticosteroid or other immunosuppressive steps (azathioprine, cyclosporine A, or cyclophosphamide). Amongst those getting steroids 2 of the patients accomplished partial and total remission (from 6), while cytotoxic drugs and cyclosporine A (CSA) treatment resulted in one and absolutely no total in addition to 5 and 7 partial remissions (from 11 and 9 patients)⁽³⁴⁾. A research study from Egypt consisted of an overall of 79 patients. Of these, a bulk had nephrotic syndrome at the time of treatment. In overall, 40 patients accomplished remission followed induction treatment with prednisolone treatment (1 mg/kg body weight for 6 weeks, followed by 0.75 mg/kg body weight

for another 6 weeks, and subsequent tapering). Mycophenolate mofetil (MMF) effectiveness was assessed in 2 research studies. One retrospective accomplice reported by Choi and associates dealt with patients either with or without concomitant steroid due to impaired kidney function or nephrotic syndrome. MMF dose differed from 1.0 to 2.0 g daily and 5 from 10 patients accomplished remission (3 total and 2 partial). Follow-up was rather brief with 7.9 months⁽³⁵⁾. In a potential research study from India MMF (target dosage 2 g/day for 6 months) was offered together with a decreased steroid dosage (0.5 mg/kg body weight as preliminary dose, overall treatment period 2-3 months). From 17 patients, 70.8% attained remission (10 total and 2 partial). Remission rates were equivalent to those getting prednisolone monotherapy (preliminary dose 1 mg/kg body weight, cumulative prednisolone dose 7.3 ± 0.9 g versus 1.9 ± 0.3 g in the MMF group). Moderate intestinal pain was observed in one patient and 2 patients in the MMF group needed hospitalization due to extreme infection. Side impacts were not reported independent of disease entity (patients with membranous nephropathy and FSGS). Subsequent regression rate was comparable in both groups too⁽³³⁾. Other research studies reporting on first-line treatment in FSGS consisted of a small number of patients just (< 10). Amongst these, one reported on single center experience with tacrolimus monotherapy in 6 patients. All topics accomplished partial remission with a mean decrease of proteinuria from 11 ± 4.5 to 2.8 ± 2.5 g/d, while serum albumin enhanced from 26.8 ± 4.6 to 37.7 ± 1.9 g/L. Throughout a follow-up duration of 12.8 months, no regression was observed⁽³⁶⁾. One research study retrospectively evaluated patients treated with either prednisolone (1 mg/kg body weight) alone, prednisolone (0.5 mg/kg body weight) with azathioprine (AZA, 2 mg/kg body weight), or CSA (3 mg/kg body weight). Remission rates were greater in the latter 2 groups, whereas adverse effects were observed in the prednisolone group (3 patients ended up being cushingoid) and leukopenia was observed in two patients being treated with AZA⁽³⁷⁾.

Plasma exchange strategy for managing FSGS:

The adoption of plasma exchange (PE) for treatment of FSGS recurrence has actually been based upon the hypothesis of the existence of distributing element (s) that might be eliminated in order to avoid the disease or deal with. In spite of research study into this causative aspect staying in a status of "cold case", PE is still a foundation in FSGS recurrence treatment, given that the 1985 report of its very first favorable application by Zimmerman⁽³⁸⁾. An organized evaluation by Ponticelli⁽²⁸⁾ revealed that PE promotes total or partial remission in 70% of children and 63% of grownups with FSGS recurrence. The majority of the evaluated research studies, nevertheless, are restricted by their retrospective or unchecked style.

We recognized organized evaluation⁽³⁹⁾ involving 77 research studies of patients with post-transplant FSGS who were treated with plasma exchange at the time of recurrence. In general, 71 % of patients attained partial or total remission from proteinuria after treatment with plasma exchange (95 % CI: 66 % to 75 %). Males were most likely to accomplish remission than women, and patients who got plasma exchange within 2 weeks of recurrence appeared most likely to accomplish remission than patients whose treatment initiation was postponed, although the latter did not reach analytical significance (the 95 % self-confidence period covered 0.9 to 5.0). Patients with greater proteinuria at recurrence (> 7 g/day) were less most likely to accomplish remission. Age and kind of kidney transplant (living vs. deceased) were not connected with remission⁽³⁹⁾.

Corticosteroids for FSGS:

Corticosteroids are the essential of treatment for idiopathic nephrotic syndrome, nevertheless; the International Study of Kidney Disease in Children research study (ISKDC) developed that just 30% of children with FSGS histology will accomplish remission with steroids⁽⁴⁰⁾. Extended high dosage intravenous methylprednisolone in combination with oral prednisolone and alkylating representatives might increase the remission rate to 60%^(41,42). These research studies were not randomized control trials.

KDIGO standards recommend for FSGS on native kidneys a 4-wk to 16-wk course of prednisone (1 mg/kg each day, with an optimum of 80 mg and a sluggish tapering in the 6 mo after remission)⁽⁴³⁾. Glucocorticoids might act to support the actin cytoskeleton, thus maintaining glomerular permselectivity⁽⁴⁴⁾ and straight minimizing podocyte apoptosis through the PI3K/Akt signal path⁽⁴⁵⁾. Effectiveness of steroid treatment in recurrent/de novo FSGS has actually never ever been examined in a randomized trial; on the other hand, considering its essential restorative function in FSGS on native kidneys, several programs have actually consisted of steroids in post-transplantation FSGS treatment.

Apart from the paper by Canaud et al⁽⁴⁶⁾, who explained a combined treatment of CyA in association with high dosage steroids and PE, Shishido et al⁽⁴⁷⁾ likewise reported a beneficial result (7/10 total remission) for pediatric patients with FSGS recurrence in reaction to a combined treatment with methylprednisolone pulses (20 mg/kg after diagnosis on 3

successive days in weeks 1, 3 and 5) and a boost in CyA target levels (location under the curve 0-- 4 4500-5500 ng/h per milliliter for the very first month, 4000 ng/h per milliliter for the next 2 mo, and 3000 ng/h per milliliter thereafter).

Mycophenolate mofetil for FSGS:

we included one large systematic review⁽⁴⁸⁾, that consisted of 3 RCTs and 18 unrestrained pre-- post research studies that utilized MMF to deal with primary FSGS. In the 3 RCTs, MMF was utilized as add-on treatment and it was normally well endured. It revealed no statistically substantial distinction in kidney function conservation, induction of proteinuria remission and upkeep of proteinuria remission as compared to the control treatments. The only statistically considerable distinction was discovered where the MMF þ corticosteroids group triggered considerably less unfavorable occasions than the CTX þ corticosteroids group (RR 1/4 0.18, 95% CI 0.05-- 0.68). When it comes to the 18 consisted of unchecked pre-post research studies, 3 of them utilized MMF as monotherapy and 15 utilized MMF as add-on treatment. Beneficial impacts were regularly revealed on kidney function conservation, induction of proteinuria remission and upkeep of proteinuria remission, whether MMF was utilized alone or in combination with other treatments. MMF was likewise well endured by individuals and reported no serious unfavorable results. All the 18 research studies particularly hired patients who depended on or resistant to steroids and/or cyclosporine. Favorable treatment results of MMF in these research studies recommended that it is an option for patients stopping working to react to existing regular treatments, the magnitude of the impact differs considerably amongst studies and adequately powered RCTs is needed to estimate the size of benefits⁽⁴⁸⁾.

REFERENCES

- [1] D'Agati VD, Kaskel FJ, Falk RJ. Focal segmental glomerulosclerosis. *N Engl J Med.* 2011;365(25):2398–411.
- [2] Cravedi P, Kopp JB, Remuzzi G. Recent progress in the pathophysiology and treatment of FSGS recurrence. *Am J Transpl.* 2013;13(2):266–74.
- [3] Artero M, Biava C, Amend W, Tomlanovich S, Vincenti F. Recurrent focal glomerulosclerosis: natural history and response to therapy. *Am J Med.* 1992;92(4):375–83.
- [4] Trachtman R, Sran SS, Trachtman H. Recurrent focal segmental glomerulosclerosis after kidney transplantation. *Pediatr Nephrol.* 2015;30:1793–1802.
- [5] Straatmann C, Kallash M, Killackey M, et al. Success with plasmapheresis treatment for recurrent focal segmental glomerulosclerosis in pediatric renal transplant recipients. *Pediatr Transplant.* 2014;18(1):29–34.
- [6] Vinai M, Waber P, Seikaly MG. Recurrence of focal segmental glomerulosclerosis in renal allograft: an in-depth review. *Pediatr Transpl.* 2010;14(3):314–25.
- [7] S. M. Korbet, "Treatment of primary FSGS in adults," *Journal of the American Society of Nephrology*, vol. 23, no. 11, pp. 1769–1776, 2012.
- [8] Gbadegesin R, Lavin P, Foreman J, Winn M. Pathogenesis and therapy of focal segmental glomerulosclerosis: an update. *Pediatr Nephrol.* 2011;26:1001–1015.
- [9] Johnstone DB, Holzman LB. Clinical impact of research on the podocyte slit diaphragm. *Nat Clin Pract Nephrol.* 2006;2:271–82.
- [10] Smoyer WE, Mundel P. Regulation of podocyte structure during the development of nephrotic syndrome. *J Mol Med.* 1998;76:172–83.
- [11] White RH, Glasgow EF, Mills RJ. Clinicopathological study of nephrotic syndrome in childhood. *Lancet.* 1970;1:1353–9.
- [12] Haraldsson B, Nyström J, Deen WM. Properties of the glomerular barrier and mechanisms of proteinuria. *Physiol Rev.* 2008;88:451–87.
- [13] Partanen TA, Arola J, Saaristo A, Jussila L, Ora A, Miettinen M, Stacker SA, Achen MG, Alitalo K. VEGF-C and VEGF-D expression in neuroendocrine cells and their receptor, VEGFR-3, in fenestrated blood vessels in human tissues. *FASEB J.* 2000;14:2087–96.

- [14] Rostgaard J, Qvortrup K. Sieve plugs in fenestrae of glomerular capillaries--site of the filtration barrier? *Cells Tissues Organs*. 2002;170:132–8.
- [15] Weinbaum S, Tarbell JM, Damiano ER. The structure and function of the endothelial glycocalyx layer. *Annu Rev Biomed*. 2007;9:121–67.
- [16] Ballermann BJ, Stan RV. Resolved: capillary endothelium is a major contributor to the glomerular filtration barrier. *J Am Soc Nephrol*. 2007;18:2432–8.
- [17] Vaughan MR, Quaggin SE. How do mesangial and endothelial cells form the glomerular tuft? *J Am Soc Nephrol*. 2008;19:24–33.
- [18] Sharma M, Sharma R, McCarthy ET, Savin VJ. “The FSGS factor: “ enrichment and in vivo effect of activity from focal segmental glomerulosclerosis plasma. *J Am Soc Nephrol*. 1999;10:552–561.
- [19] Le Berre L, Godfrin Y, Günther E, Buzelin F, Perretto S, Smit H, Kerjaschki D, Usal C, Cuturi C, Souillou JP, et al. Extrarenal effects on the pathogenesis and relapse of idiopathic nephrotic syndrome in Buffalo/Mna rats. *J Clin Invest*. 2002;109:491–498.
- [20] Gallon L, Leventhal J, Skaro A, Kanwar Y, Alvarado A. Resolution of recurrent focal segmental glomerulosclerosis after retransplantation. *N Engl J Med*. 2012;366:1648–1649.
- [21] Wei C, Möller CC, Altintas MM, Li J, Schwarz K, Zacchigna S, Xie L, Henger A, Schmid H, Rastaldi MP, et al. Modification of kidney barrier function by the urokinase receptor. *Nat Med*. 2008;14:55–63.
- [22] Wei C, El Hindi S, Li J, Fornoni A, Goes N, Sageshima J, Maignel D, Karumanchi SA, Yap HK, Saleem M, et al. Circulating urokinase receptor as a cause of focal segmental glomerulosclerosis. *Nat Med*. 2011;17:952–960.
- [23] Thunø M, Macho B, Eugen-Olsen J. suPAR: the molecular crystal ball. *Dis Markers*. 2009;27:157–172.
- [24] Maas RJ, Wetzels JF, Deegens JK. Serum-soluble urokinase receptor concentration in primary FSGS. *Kidney Int*. 2012;81:1043–1044.
- [25] Bock ME, Price HE, Gallon L, Langman CB. Serum soluble urokinase-type plasminogen activator receptor levels and idiopathic FSGS in children: a single-center report. *Clin J Am Soc Nephrol*. 2013;8:1304–1311.
- [26] McCarthy ET, Sharma M, Savin VJ. Circulating permeability factors in idiopathic nephrotic syndrome and focal segmental glomerulosclerosis. *Clin J Am Soc Nephrol*. 2010;5:2115–2121.
- [27] Delville M, Sigdel TK, Wei C, Li J, Hsieh SC, Fornoni A, Burke GW, Bruneval P, Naesens M, Jackson A, et al. A circulating antibody panel for pretransplant prediction of FSGS recurrence after kidney transplantation. *Sci Transl Med*. 2014;6:256ra136.
- [28] Ponticelli C. Recurrence of focal segmental glomerular sclerosis (FSGS) after renal transplantation. *Nephrol Dial Transplant*. 2010;25:25–31.
- [29] Carraro M, Caridi G, Bruschi M, et al. Serum glomerular permeability activity in patients with podocin mutations (NPHS2) and steroid-resistant nephrotic syndrome. *J Am Soc Nephrol*. 2002;13(7):1946–52.
- [30] Raphaël JC, Chevret S, Hughes RA, Annane D. Plasma exchange for Guillain-Barré syndrome. *Cochrane Database Syst Rev*. 2002;2:CD001798.
- [31] First MR. Living-related donor transplants should be performed with caution in patients with focal segmental glomerulosclerosis. *Pediatr Nephrol*. 1995;9(Suppl):S40–2.
- [32] J. J. Rydel, S. M. Korbet, R. Z. Borok, and M. M. Schwartz, “Focal segmental glomerular sclerosis in adults: presentation, course, and response to treatment,” *American Journal of Kidney Diseases*, vol. 25, no. 4, pp. 534–542, 1995.
- [33] L. Senthil Nayagam, A. Ganguli, M. Rathi et al., “Mycophenolate mofetil or standard therapy for membranous nephropathy and focal segmental glomerulosclerosis: a pilot study,” *Nephrology Dialysis Transplantation*, vol. 23, no. 6, pp. 1926–1930, 2008.

- [34] C. Ponticelli, M. Villa, G. Banfi et al., "Can prolonged treatment improve the prognosis in adults with focal segmental glomerulosclerosis?" *American Journal of Kidney Diseases*, vol. 34, no. 4, pp. 618–625, 1999.
- [35] M. J. Choi, J. A. Eustace, L. F. Gimenez et al., "Mycophenolate mofetil treatment for primary glomerular diseases," *Kidney International*, vol. 61, no. 3, pp. 1098–1114, 2002.
- [36] N. Duncan, A. Dhaygude, J. Owen et al., "Treatment of focal and segmental glomerulosclerosis in adults with tacrolimus monotherapy," *Nephrology Dialysis Transplantation*, vol. 19, no. 12, pp. 3062–3067, 2004.
- [37] D. S. Goumenos, G. Tsagalis, A. M. El Nahas et al., "Immunosuppressive treatment of idiopathic focal segmental glomerulosclerosis: a five-year follow-up study," *Nephron Clinical Practice*, vol. 104, no. 2, pp. c75–c82, 2006.
- [38] Zimmerman SW. Plasmapheresis and dipyridamole for recurrent focal glomerular sclerosis. *Nephron*.1985;40:241–245.
- [39] Abdullah Kashgary, Jessica M. Sontrop, Lihua Li, Ahmed A. Al-Jaishi, Zainab N. Habibullah, Roaa Alsolaimani and William F. Clark. The role of plasma exchange in treating post-transplant focal segmental glomerulosclerosis: A systematic review and meta-analysis of 77 case-reports and case-series. *BMC Nephrology* DOI: 10.1186/s12882-016-0322-7.
- [40] ISKDC . Nephrotic syndrome in children: prediction of histopathology from clinical and laboratory characteristics at time of diagnosis. A report of the International Study of Kidney Disease in Children. *Kidney Int*. 1978;13:159–65.
- [41] Mendoza SA, Tune BM. Treatment of childhood nephrotic syndrome. *J Am Soc Nephrol*. 1992;3:889–94.
- [42] Tune BM, Mendoza SA. Treatment of the idiopathic nephrotic syndrome: regimens and outcomes in children and adults. *J Am Soc Nephrol*. 1997;8:824–32.
- [43] Kidney Disease Improving Global Outcomes (KDIGO) Glomerulonephritis Work Group. KDIGO Clinical Practice Guideline for Glomerulonephritis. *Kidney Int Suppl*. 2012;2:139–274.
- [44] Ransom RF, Lam NG, Hallett MA, Atkinson SJ, Smoyer WE. Glucocorticoids protect and enhance recovery of cultured murine podocytes via actin filament stabilization. *Kidney Int*. 2005;68:2473–2483.
- [45] Yu-Shengyou Y. Dexamethasone inhibits podocyte apoptosis by stabilizing the PI3K/Akt signal pathway. *Biomed Res Int*. 2013;2013:326986.
- [46] Canaud G, Zuber J, Sberro R, Royale V, Anglicheau D, Snaoudj R, Gaha K, Thervet E, Lefrère F, Cavazzana-Calvo M, et al. Intensive and prolonged treatment of focal and segmental glomerulosclerosis recurrence in adult kidney transplant recipients: a pilot study. *Am J Transplant*. 2009;9:1081–1086.
- [47] Shishido S, Satou H, Muramatsu M, Hamasaki Y, Ishikura K, Hataya H, Honda M, Asanuma H, Aikawa A. Combination of pulse methylprednisolone infusions with cyclosporine-based immunosuppression is safe and effective to treat recurrent focal segmental glomerulosclerosis after pediatric kidney transplantation. *Clin Transplant*. 2013;27:E143–E150.
- [48] Lau, Polly H.X. Ma, Xinyin Wu, Vincent C.H. Chung, and Samuel Y.S. Wong. Mycophenolate mofetil for primary focal segmental glomerulosclerosis: systematic review Emily W.Y. *Ren Fail*, 2013; 35(6): 914–929.